

# Collagen and PRP in Partial Thickness Rotator Cuff Injuries. Friends or Only Indifferent Neighbours? Randomized Controlled Trial

Piotr Godek (✉ [piotrgodek.smc@gmail.com](mailto:piotrgodek.smc@gmail.com))

Sutherland Medical Center

Beata Szczepanowska-Wolowicz

The Jan Kochanowski University

Dominik Golicki

Medical University of Warsaw

---

## Research Article

**Keywords:** rotator cuff, PRP, collagen, conservative treatment, tendinopathy

**Posted Date:** August 11th, 2021

**DOI:** <https://doi.org/10.21203/rs.3.rs-770124/v1>

**License:**  This work is licensed under a Creative Commons Attribution 4.0 International License.

[Read Full License](#)

---

# Abstract

**INTRODUCTION:** Partial thickness rotator cuff injuries (PTRCI) is the sum of degenerative, overload and microtrauma processes, external supply of collagen and platelet-rich plasma (PRP) could potentially counteract deterioration of degenerative tendinopathy.

**AIM:** Comparison of the effectiveness: collagen with PRP, PRP alone, collagen alone in the treatment of PTRCI.

**METHODS:** Ninety patients with PTRCI treated with US-guided injections into the shoulder bursa every consecutive week: Group A - collagen with PRP (n=30), B - collagen alone (n=30), C - PRP alone (n=30). Primary outcomes: numeric rating scale (NRS), QuickDash and EQ-5D-5L questionnaires in control points: IA (initial assessment), T1, T2, T3 – after 6, 12 and 24 weeks, respectively. Secondary outcomes: number of patients with loss of RC continuity, number of regenerated RC between IA and T3.

**RESULTS:** No statistical difference between groups in primary outcomes, tendency for further improvement in A and C group (opposite to group B) between T2 and T3. The RC discontinuity (n = 3, one case in each group) and RC regeneration (n = 65; 73%, 67% and 77%, in group A, B and C, respectively).

**CONCLUSIONS:** Combined therapy of collagen and PRP in PTRCI is not more effective than monotherapies with collagen or PRP.

(clinicaltrials.gov - NCT04492748)

## Introduction

Rotator cuff injuries (RCI) ranks third in the population prevalence among musculoskeletal system pathologies (16%) after lumbar spine pain (25%) and knee pain (19%). Depending on the source, the prevalence of RCI is from 5 to 39%. It increases very clearly with age and in patients over 60 years of age reaches over 30%, with a great majority being described as rotator cuff tendinopathy (RCT), mostly in the form of partial thickness RCI (PTRCI) as an emanation of the degenerative process [1].

Over 85% of the dry mass of the rotator cuff tendons is type I collagen. Damage, disorganization of collagen fibers and a negative metabolic balance of collagen underlie the macroscopic lesions visible in ultrasound (US) or resonance imaging (RI) [2].

Most often, the PTRCI concerns the supraspinatus tendon (SSP), which is the crucial factor in centering of the humeral head in joint glenoid during the act of upper limb elevation. In traumatic cases also subscapularis (SSC) and infraspinatus (ISP) tendons are affected often with long head biceps (LHB) instability. There are several reasons for the degenerative process leading initially to edema, micro-perforations and then full thickness tendon lesions: 1) natural age-related weakening of blood supply near the SSP insertion, 2) concomitant degenerative spurs of acromioclavicular joint or acromion shape as a direct cause of the subacromial impingement, 3) disturbed muscle timing between RC and deltoid

usually associated with cervical spondylosis (scapular dyskinesia), 4) shoulder joint multidirectional instability as a result of capsule-ligamentous elements laxity and disturbed contact of joint surfaces with RC posterior impingement. The consequences of RCI are further destabilization of the shoulder, scapular dyskinesia, upper and anterior migration of humeral head followed by subacromial bursitis. The clinical picture of PTRCI includes shoulder pain radiating to the deltoid area and even to the elbow both at rest and at strain, weakening of muscular strength, impaired limb function and disability of self-service. Due to the risk of surgical treatment, reduced strength of RC tendons affected by the degenerative process and a significant risk of injury recurrence, conservative treatment of PTRCI is the first choice, especially for inactive patients over the age of 60 years. It assumes the alleviation of inflammatory symptoms (physical therapy, general and local pharmacotherapy - most often steroid injections), attempts of regenerative treatment as: Platelet Rich Plasma (PRP), collagen injections, autologous conditioned serum (ACS) and rehabilitation (muscular centering of the humeral head, developing compensatory movement patterns).

Reports on PRP show its positive effects, both alleviating symptoms and slowing down the process of further degeneration of the tendon, demonstrating its advantage over steroid administration or prolotherapy [3, 4, 5].

Another form of therapy aimed at suppressing the negative balance of collagen metabolism is to supply collagen in the form of an injection in the vicinity of the injured tissue (into the tendon itself or into the subacromial bursa). The premises for this type of injection are reports showing a reduction in pain after collagen injections compared to steroid injections and a significant acceleration of the proliferation and migration of tenocytes cultured in an exogenous collagen environment in vitro [6, 7]. The same is true for synergic effects of collagen and PRP confirmed in multiple studies utilized tendon-like cell models, where increased cell proliferation was observed with the addition of various PRP products. This suggests that PRP products have a positive effect on the cell's mitogenic activity, collagen production and optimization of the collagen I/III ratio [8].

These positive effects and their consequences for clinical significance have not yet been demonstrated in clinical studies and it was our main premise to initiate comparative study about the effectiveness of three treatment concepts: collagen with PRP, collagen alone, PRP alone, in the treatment of PTRCI.

## **Material And Methods**

The study design was single center open randomized controlled trial. The protocol of the trial was approved by the Bioethics Committee at the Faculty of Health Sciences of the Jan Kochanowski University in Kielce (Reference No. 15/2020, May 18, 2020). All experiments were performed in accordance with and following the Declaration of Helsinki Principles. All methods were performed in accordance with the relevant guideline and regulations. Written informed consent was obtained from all participants prior to injections and the publication of their individual data. The study was performed in Sutherland Medical Center (SMC), Warsaw, Poland. The trial was registered in Clinicaltrials.gov

(NCT04492748) on 20/07/2020 (Initial Release), last update 03/10/2021. Unique Protocol ID: SMC2020001. Brief title: Rotator Cuff Tendinopathy Conservative Treatment With Collagen, PRP or Both (RCCT).

## Inclusion criteria:

- clinical signs and symptoms of rotator cuff pathology
- an adult person consenting to injections
- partial thickness rotator cuff injury confirmed by ultrasound examination without coexisting severe pathologies (systemic inflammatory disease, malignancy, severe stage of osteoarthritis)
- no traumatic event

## Exclusion criteria:

- full thickness rotator cuff injury
- acute, traumatic injuries requiring surgical treatment
- coexisting injuries of the shoulder joint requiring other intervention
- severe pathologies of the shoulder of another origin (systemic inflammatory disease, malignancy, severe stage of osteoarthritis )
- no consent

Three groups of patients, each containing 30 participants, were enrolled in the study. Patients meeting the inclusion criteria were allocated randomly according to the computer-generated randomization list (block randomization; block size = 6). No changes of allocation and no changes in the methodology of the study took place throughout the study.

All data were collected at SMC Clinic. During the Initial Assessment (IA), patients were asked to evaluate intensity of the pain (Numeric Rating Scale, NRS, range from 0 (no pain) to 10 (extreme pain) and to complete widely used, validated questionnaires: QuickDash (0-50) and the EQ-5D-5L (descriptive part and EQ-VAS 0-100). US-examination of the shoulder was performed with the usage of Alpinion E-CUBE 12 device, linear transducer L3-12H (3-12 MHz).

SSP tendon width (cross-section in mm) was measured in the internal rotation position of the arm. We distinguished following ultrasound patterns of PTRCI: bursa- sided (BS), joint – sided (JS), intra-tendon (IT) and oblique or focal (OF). The measurement in BS and JS types was performed in the narrowest point (follow- up measure estimates tendency for increase of the RC width as a sign of regeneration). In

IT or OF type of injury the measurement was performed at the thickest point of RC (follow-up measure estimates tendency for reduction of inflammatory and oedematous overgrowth of the RC as a sign of regeneration).

Each group was treated by three US-guided injections into the subacromial bursa using the in-plane technique. Injections were performed every consecutive week by the same physician (P.G.). Group A - collagen (3 vials of Collagen MD Shoulder – total 6 cc) simultaneously with PRP GLOFINN (10 cc whole blood, double centrifugate, leukocyte rich PRP, volume of PRP – 2 cc); Group B - collagen alone (3 vials of Collagen MD Shoulder); Group C - PRP GLOFINN alone.

All patients were allowed to continue a rehabilitation protocol with preservation of safe, pain-free range of motion, postural exercises, scapular stabilization exercises. Prohibited were any exercises with resistance which would compromise the healing process of RC.

Primary outcomes included Numeric Rating Scale, NRS (0-10; 0-no pain, 10-maximal pain), QuickDash questionnaire (0-50; 0-no disability, 50 maximal disability), EQ-5D-5L questionnaire (five dimensions: MO-mobility, SC-self-care, UA-usual activities, PD-pain and discomfort, AD- anxiety and depression; each dimension with five levels of limitations: 1-no limitation, 5-maximal limitation; visual analogue scale EQ-VAS 0-100; 0 – the worst health status, 100-optimal health status). Follow-up schedule for primary outcomes: Initial assessment (IA), 6, 12 and 24 weeks after last injection.

Secondary outcomes included percentage of patients in each group where the RC continuity was preserved with desired evolution of RC cross-section width and percentage of patients who had US signs of RC regeneration. Secondary outcomes were assessed at IA and T3.

The power of the test was set at 0.8 and the significance level at 0.05, assuming that the effect size was  $f = 0.35$ . This allowed us to establish that the research sample for the three compared groups should not be smaller than 90 subjects (each group with 30 participants).

Descriptive statistics for demographic data, ANOVA test to proof initial comparability of the groups and to check possible significant differences between groups according to age, NRS, QuickDash and EQ-5D-5L questionnaire VAS were performed using IBM SPSS version 25.

In the analysis of the collected research material, the one-way ANOVA test was used, which allowed us to check whether one independent variable (factor) affects the results of the dependent variable. The test results allowed us to determine whether the mean scores of the scales for individual control points differ statistically significantly between the groups. In order to determine between which groups there is a statistically significant difference, Tukey's post-hoc test was used. A calculation of the difference in value between the baseline IA and the T3 point for every single patient was also performed, and then the mean values of this difference was taken to compare primary outcomes in the groups.

## Results

One hundred one patient were screened for eligibility. Ninety patients meeting inclusion criteria were randomized. One person from group A did not finish the therapy (for reason other than therapy intolerance) and had no T1, T2 and T3 observations. Two persons quit the study after T1 (group C/JS and group A/IT). One person left the follow-up appointment after T2 due to lack of improvement and asked for a change of therapy (group C/OF). Two patients faced total RC tear before the end of the observation – between T2 and T3 (group C/JS and A/IT) and one patient was found to have had complete RC injury at the T3 visit. Finally, eight people did not obtain the T3 control; one person did not complete the therapy, three people dropped out of further control after T1 (two patients experienced a complete tear of the RC between the visit T2 and T3) - group C/JS and group A/IT, one person from group C/OF asked to change therapy after T2 control), and one person from group A/JS refused control T3.

Recruitment and follow-up process presents Fig. 1.

The treatment has been accomplished by 89 patients (99%). All check-up visits were passed by 91.1% of patients. In 82 patients who completed therapy and obtained T3 control, three SSP total injuries were observed (3.6%). There was no participant cross-over.

Table 1 presents demographic characteristics. ANOVA test didn't reveal any significant statistical difference according to age, NRS, QuickDash and EQ-5D-5L VAS mean values in IA between groups.

Table 1

## Demographic characteristics.

<b>Total number of patients, n</b>	<b>90</b>
Female, n (%)	42 (46.7)
Age, years, mean $\pm$ SD (range)	54.5 $\pm$ 14.7 (24–91)
Duration of complaints weeks, mean $\pm$ SD (range)	21.8 $\pm$ 28.5 (1-230)
RC tendopathy phase, n (%):	
Acute phase patients,	10 (11.1)
Subacute phase patients	27 (30.0)
Chronic phase patients	53 (58.9)
Injury type, n (%):	
Bursa Side	5 (5.6)
Joint Side	49 (54.4)
Intratendinous	22 (24.4)
Oblique and focal	14 (15.6)
Side of complaints, n (%):	
Right	49 (54.4)
Left	41 (45.6)
Dominant limb, n (%):	
Right	84 (93.3)
Left	2 (2.2)
Both	4 (4.4)

Figure 2 presents the mean NRS evolution in specific groups. A reduction in pain intensity is seen mostly in the first 6 weeks of follow-up but no significant statistical differences between groups were noticed in ANOVA. There is a slight tendency in A and C group for further improvement beyond T2.

Figure 3 presents the mean QuickDash evolution in specific group where similar pattern of mean values reduction is observed also without significant statistical differences between groups in ANOVA test for QuickDash main questionnaire.

Figure 4 presents the mean EQ-5D-5L VAS evolution in specific groups. No statistically significant differences were found. The dynamics of changes during six weeks after last injection is similarly more intense.

The ANOVA test for the EQ-5D-5L Index showed a statistically significant difference in baseline values (IA) between the groups, while no statistically significant differences were observed in the control points.

In order to check between which groups there are statistically significant differences, the post hoc test was used. The Games-Howell test was chosen due to the failure to meet the assumption of homogeneity of variance in the analyzed groups. The analysis showed differences ( $p < 0.05$ ) between groups A (0.892) and C (0.816). It is worth noting that between groups A (0.892) and B (0.820) there is also a similar difference between the mean EQ-5D-5L indices, but the analysis showed no statistical significance ( $p = 0.063$ ) [Fig. 5].

A calculation of the differences between the baseline IA and T3 values for every single patient was also performed. A mean value of this differences for each studied group were calculated. Figure 6 presents differences in the mean initial and final values for primary outcomes in the groups. Group B shows the highest differences in all scales, although the ANOVA test did not show statistical significance between the groups.

Lost continuity of RC between IA and T3 was found in three cases (one in each group) and the number of cases with RC regeneration confirmed in ultrasound was: A-22, B-20, C-23.

Mean increase of RC width in BS and JS type of injury for specific groups was: A – 0.7 mm, B – 0.2 mm, C – 1.3 mm. There is statistically significant difference for B and C ( $p < 0.05$ ) in ANOVA test. [Fig. 7].

Mean reduction of width for IT and OF type of injury for specific groups was: A – 0.7 mm, B – 0.9 mm, C – 0.3 mm. No statistically significant difference between groups in ANOVA test were found [Fig.8].Fig.8. Mean reduction of width for IT and OF type of injury for specific groups.

No significant harms, complication or unintended effects of the treatment were reported.

## Discussion

Conservative treatment of PTRCI with injections of collagen and PRP as monotherapy or combined therapy showed no significant difference in efficacy.

The strength of our study is based on the first ever performed test in vivo whether really exist the potential synergy between PRP and collagen delivered into subacromial bursa in terms of tendon regeneration by randomized control trial (the authors did not find a similar study in the literature). In addition to the well-validated subjective assessment questionnaires, an ultrasound examination with six-month observation was used, which seems to be long enough to observe changes in echogenicity and possible change in tendon thickness.

The weakness of the study is certainly a small group of participants, imperfections in the methodology of RC thickness measurement in ultrasound as an operator dependent. The bias is mostly connected with difficulties to obtain the same cross-section point of reference for precise test-retest measurement.



Another bias of the study which may modify the results is the wide margin of tolerance according to rehabilitation protocol which was implemented for the participants before or in the course of the study beyond of our control, as well a sport or working activities exerted by many of them against recommendations. There were also no restrictions on taking painkillers when needed during observations period.

Degenerative rotator cuff tendinopathy appearing as PTRCI is a condition challenging to treat, mainly because of the poor regenerative potential of the tendons correlated with aging. It has been described many other factors contributing to treatment failure like: overload in the rehabilitation process, drugs (i.e. quinolones), alcohol intake, smoking, corticosteroids [9].

For over two decades there have been a growing interest in biologically active substances like growth factors, stem cells or autologous conditioned serum [10].

There are many publications about PRP's potential enhancement of healing potential after surgical repairing of RCI and decreasing ratio of re-tear. However, the data are conflicting [11, 12, 13, 14].

In vitro culture experiments clearly confirm the anabolic effect of PRP on the healing of RC lesions through cell proliferation and synthesis of collagen I [15].

However in vivo, especially without RC repair there is much confusion and the conclusions are conflicting. A protocol of PRP usage, similar to our study, brought by Freitag et al. (2014) in a case report of 60 years old patient treated with three doses of PRP for PTRCI in weekly intervals but administered not into bursa but into the partial supraspinatus tear using a lateral approach. He followed-up the outcomes throughout 52 weeks. The NRS, patient percentage perceived improvement (PPPI) and a handheld isometric dynamometer assessment of RC strength was recorded in follow-up intervals occurring at 6th, 17th, 25th and 52nd weeks revealing the best PPPI up to 90% in 17th week and slightly worse at 52nd week (70%) [16].

Scarpone et al. presented open study prospective trial without control group on 19 patients treated with a single ultrasound-guided, intralesional injection of PRP in RCT reporting satisfying results in 18 cases up to 52 weeks of follow-up [17].

The similar outcomes were achieved by Wesner et al. in their pilot study on a small group of nine participants versus control group placebo (7 with PRP and 2 with saline) in the 6 months follow-up [18].

Kesikburun et al. who also used single injection of PRP performed RCT with 1-year follow-up, where PRP injections versus placebo (saline) were injected into subacromial bursa in the group of 40 patients (20 – PRP versus 20 – saline). Injection therapy was followed by 6 weeks rehabilitation program. They found no significant differences in improving quality of life, pain, disability, and shoulder range of motion than placebo in patients with PTRCI who were treated with an exercise program [19].

However, all the above-cited studies did not have subsequent imaging control to objectify tendon regeneration.

It seems to be reasonable to raise a question of insufficient dose of single shot PRP (especially if a low volume whole blood set was used), as a possible reason of unsatisfied results. Similar questions have been raised with respect to the type of PRP that may be optimal for promoting regeneration that was confirmed in laboratory comparative studies between low and high leucocyte PRP [20, 21].

The authors have found only one prospective study performed by Nesterova et al. about the usage of collagen GUNA MD injections in PTRCI, where in 22 patients treated with intrabursal injections of total 20 vials throughout 8 weeks achieved satisfactory results by 73% of patients with 77% of recovered lesions confirmed in US [6].

Our study showed clearly that the healing potential of RC no matter how weak still exists and can be activated or augmented by external delivery of biologic active substrates although without clear difference between monotherapy or combined therapy. However many questions about the optimal PRP composition, collagen dose, administration sequence (mixture or sequential administration) and injection location depending on the type of RC injury (intraarticular or intrabursal) remain open. The most interesting seem to be unknown connection between structural integrity of RC and clinical outcomes.

## Conclusions

Combined therapy of collagen and PRP in PTRCI is not more effective than separate therapies.

## Declarations

## Funding

The authors received no financial support for the research, authorship, and publication of this article.

## Declaration of Conflicting Interests

The authors declare no conflicting interests for research, authorship, and publication of this article.

## References

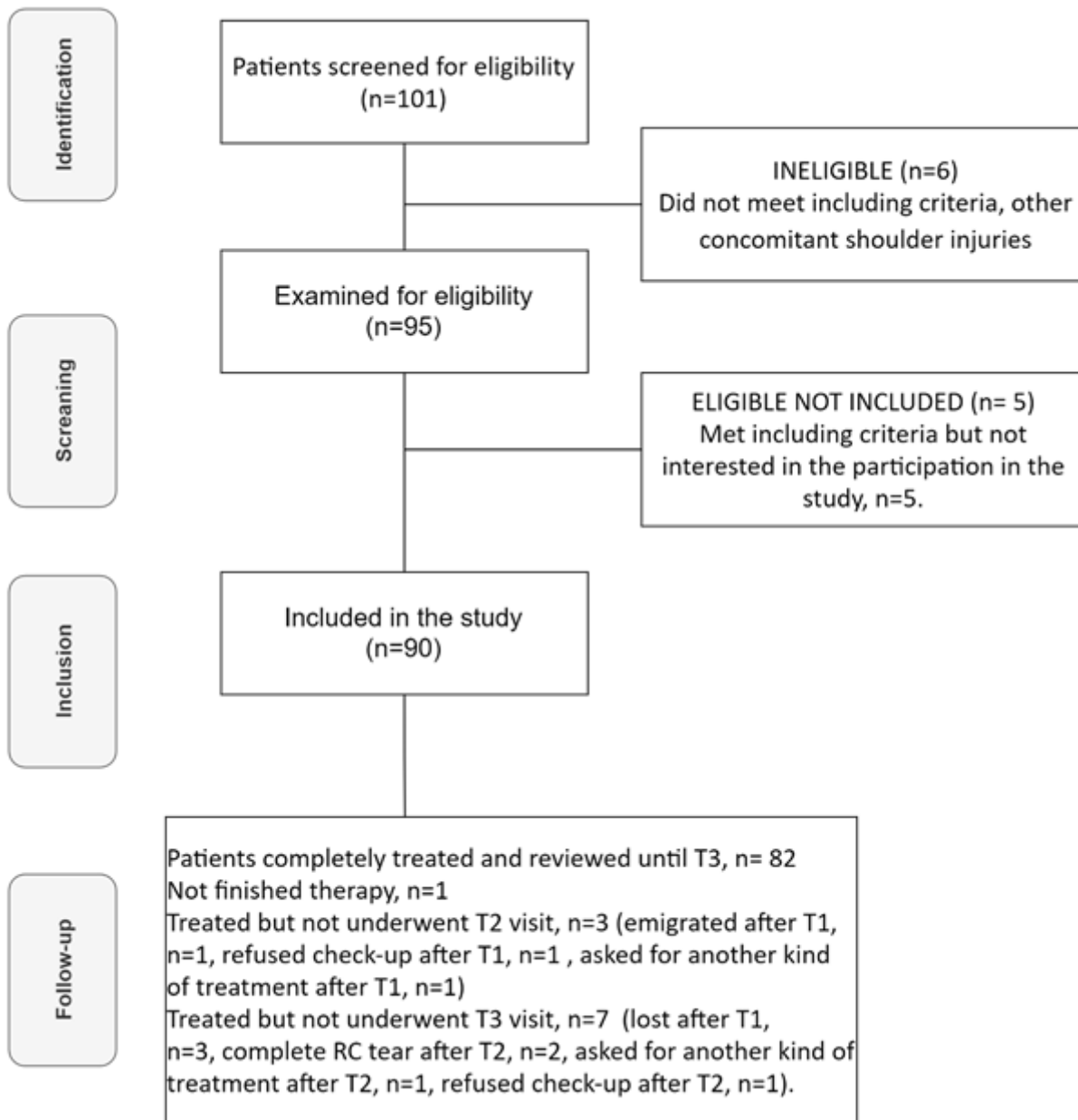
1. Longo, U. G., Berton, A., Papapietro, N., Maffulli, N. & Denaro, V. Epidemiology, genetics and biological factors of rotator cuff tears. *Med Sport Sci* 2012;57:1–9. doi: 10.1159/000328868. Epub 2011 Oct 4. PMID: 21986040.
2. Thankam, F. G., Dilisio, M. F., Gross, R. M. & Agrawal, D. K. Collagen I: a kingpin for rotator cuff tendon pathology. *Am J Transl Res*. 2018 Nov15;10(11):3291–3309. PMID: 30662587; PMCID:

PMC6291732.

3. Kim, S. J. *et al.* Effect of platelet-rich plasma on the degenerative rotator cuff tendinopathy according to the compositions. *J Orthop Surg Res.* 2019 Dec 2;14(1):408. doi: 10.1186/s13018-019-1406-4. PMID: 31791360; PMCID: PMC6889570.
4. Cross, J. A. *et al.* Leukocyte-Reduced Platelet-Rich Plasma Normalizes Matrix Metabolism in Torn Human Rotator Cuff Tendons. *Am J Sports Med*, **43** (12), 2898–2906 Epub 2015 Oct 12. PMID: 26460099. (2015 Dec).
5. Sari, A. & Eroglu, A. Comparison of ultrasound-guided platelet-rich plasma, prolotherapy, and corticosteroid injections in rotator cuff lesions. *J Back Musculoskelet Rehabil.* 2020;33(3):387–396. doi: 10.3233/BMR-191519. PMID: 31743987.
6. Nesterova, R., Rashkov, R. & Petranova, T. Clinical and sonographic assessment of the effectiveness of Guna Collagen MDs injections in patients with partial thickness tear of the rotator cuff. *Physiological Regulating Medicine*, 2016–2017; 35–37.
7. Randelli, F. *et al.* Effect of a Collagen-Based Compound on Morpho-Functional Properties of Cultured Human Tenocytes. *Cells.* 2018 Dec 6;7(12):246. doi: 10.3390/cells7120246. PMID: 30563214; PMCID: PMC6316559.
8. Baksh, N., Hannon, C. P., Murawski, C. D., Smyth, N. A. & Kennedy, J. G. Platelet-rich plasma in tendon models: a systematic review of basic science literature. *Arthroscopy*, **29** (3), 596–607 <https://doi.org/10.1016/j.arthro.2012.10.025> (2013 Mar).
9. Canata, G. L., d'Hooghe, P. & Hunt, K. J. *Muscle and Tendon Injuries Evaluation and Management* pp. 113–114 (Springer, 2017).
10. Rohman, M. L. & Snow, M. Use of biologics in rotator cuff disorders: Current concept review. *J Clin Orthop Trauma*, **15**, 1981–1988 <https://doi.org/10.1016/j.jcot.2021.05.005> (2021 May).
11. Malavolta, E. A. *et al.* Clinical and Structural Evaluations of Rotator Cuff Repair With and Without Added Platelet-Rich Plasma at 5-Year Follow-up: A Prospective Randomized Study. *Am J Sports Med*, **46** (13), 3134–3141 Epub 2018 Sep 20. PMID: 30234999. (2018 Nov).
12. Saltzman, B. M. *et al.* Does the Use of Platelet-Rich Plasma at the Time of Surgery Improve Clinical Outcomes in Arthroscopic Rotator Cuff Repair When Compared With Control Cohorts? A Systematic Review of Meta-analyses. *Arthroscopy*. 2016 May;32(5):906–18. doi: 10.1016/j.arthro.2015.10.007. Epub 2015 Dec 23. PMID: 26725454.
13. Vavken, P. *et al.* Platelet-Rich Plasma Reduces Retear Rates After Arthroscopic Repair of Small- and Medium-Sized Rotator Cuff Tears but Is Not Cost-Effective. *Am J Sports Med*, **43** (12), 3071–3076 <https://doi.org/10.1177/0363546515572777> (2015 Dec).
14. Goldenberg, B. T. *et al.* Biologics to Improve Healing in Large and Massive Rotator Cuff Tears: A Critical Review. *Orthop Res Rev.* 2020 Oct 13;12:151–160. doi: 10.2147/ORR.S260657. PMID: 33116954; PMCID: PMC7568683.
15. Pauly, S., Klatte-Schulz, F., Stahnke, K., Scheibel, M. & Wildemann, B. The effect of autologous platelet rich plasma on tenocytes of the human rotator cuff. *BMC Musculoskelet Disord.* 2018 Nov

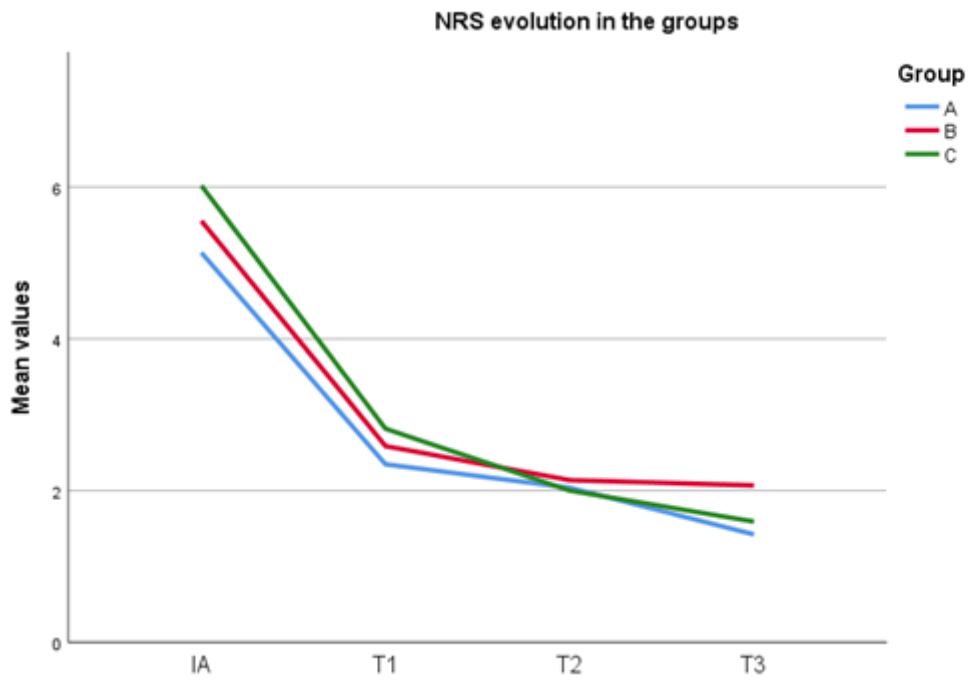
- 30;19(1):422. doi: 10.1186/s12891-018-2339-5. PMID: 30497435; PMCID: PMC6267832.
16. Freitag, J., Lenssen, R., Slimmon, D. & Balster, S. The effect of platelet-rich plasma injections in the non-surgical treatment of a partial rotator cuff tear. *Int J Case Rep Images*, **5** (7), 524–530 (2014).
  17. Scarpone, M. *et al.* Effectiveness of Platelet-rich Plasma Injection for Rotator Cuff Tendinopathy: A Prospective Open-label Study. *Glob Adv Health Med*, **2** (2), 26–31 <https://doi.org/10.7453/gahmj.2012.054> (2013 Mar).
  18. Wesner, M. *et al.* A Pilot Study Evaluating the Effectiveness of Platelet-Rich Plasma Therapy for Treating Degenerative Tendinopathies: A Randomized Control Trial with Synchronous Observational Cohort. *PLoS One*. 2016 Feb 5;11(2):e0147842. doi: 10.1371/journal.pone.0147842. PMID: 26849812; PMCID: PMC4743976.
  19. Kesikburun, S., Tan, A. K., Yilmaz, B., Yaşar, E. & Yazicioğlu, K. Platelet-rich plasma injections in the treatment of chronic rotator cuff tendinopathy: a randomized controlled trial with 1-year follow-up. *Am J Sports Med*. 2013 Nov;41(11):2609-16. doi: 10.1177/0363546513496542. Epub 2013 Jul 26. PMID: 23893418.
  20. Cross, J. A. *et al.* Leukocyte-Reduced Platelet-Rich Plasma Normalizes Matrix Metabolism in Torn Human Rotator Cuff Tendons. *Am J Sports Med*, **43** (12), 2898–2906 Epub 2015 Oct 12. PMID: 26460099. (2015 Dec).
  21. Martin, P. & Leibovich, S. J. Inflammatory cells during wound repair: the good, the bad and the ugly. *Trends Cell Biol*. 2005 Nov;15(11):599–607. doi: 10.1016/j.tcb.2005.09.002. Epub 2005 Oct 3. PMID: 16202600.

## Figures



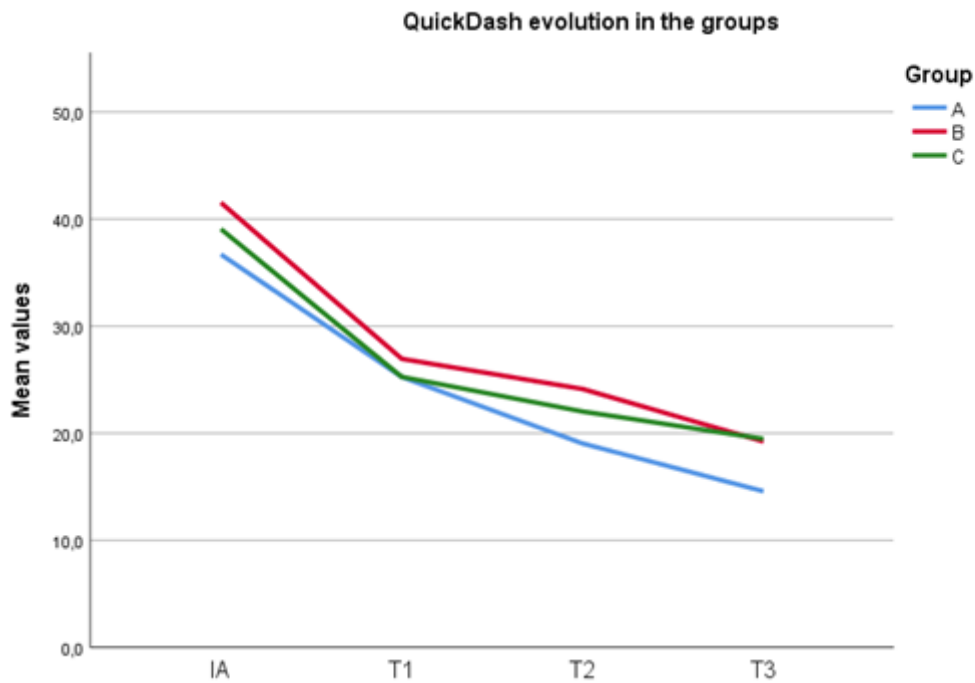
**Figure 1**

Enrollment and follow-up process.



**Figure 2**

Mean NRS evolution in specific groups.



**Figure 3**

Mean QuickDash evolution in specific groups.

EQ-5D-5L VAS evolution in the groups

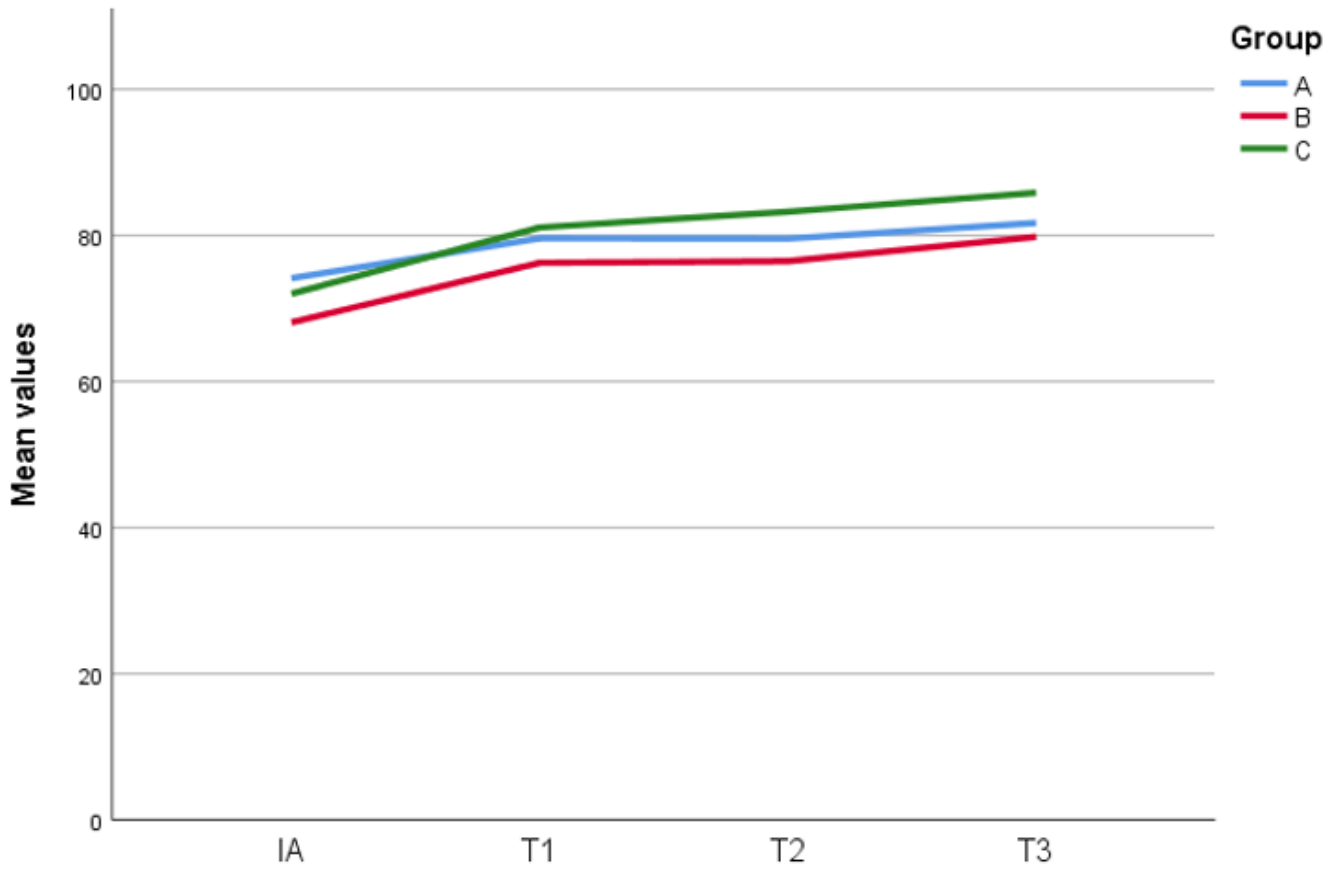


Figure 4

Mean EQ-5D-5L VAS evolution in specific groups.

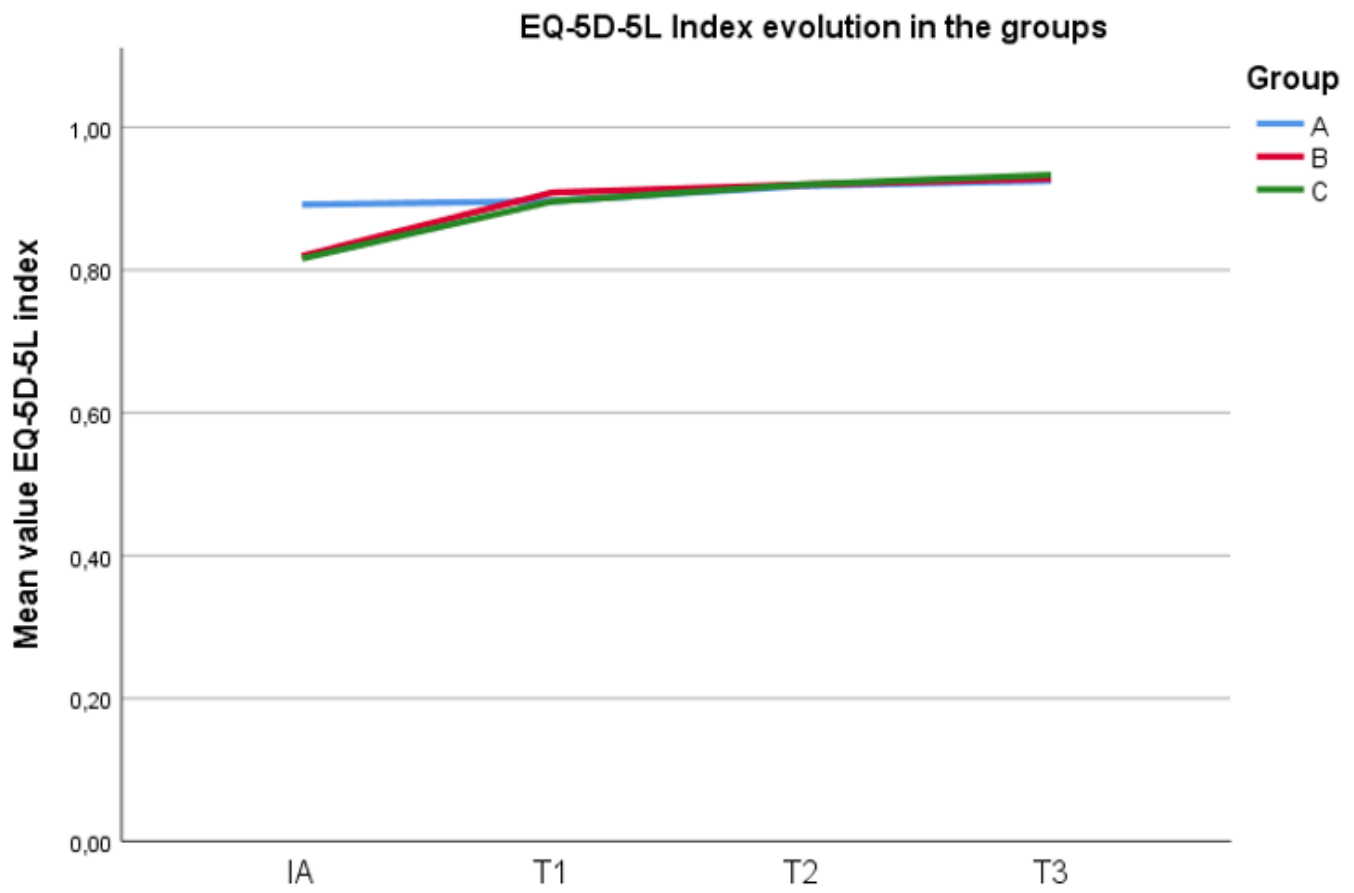
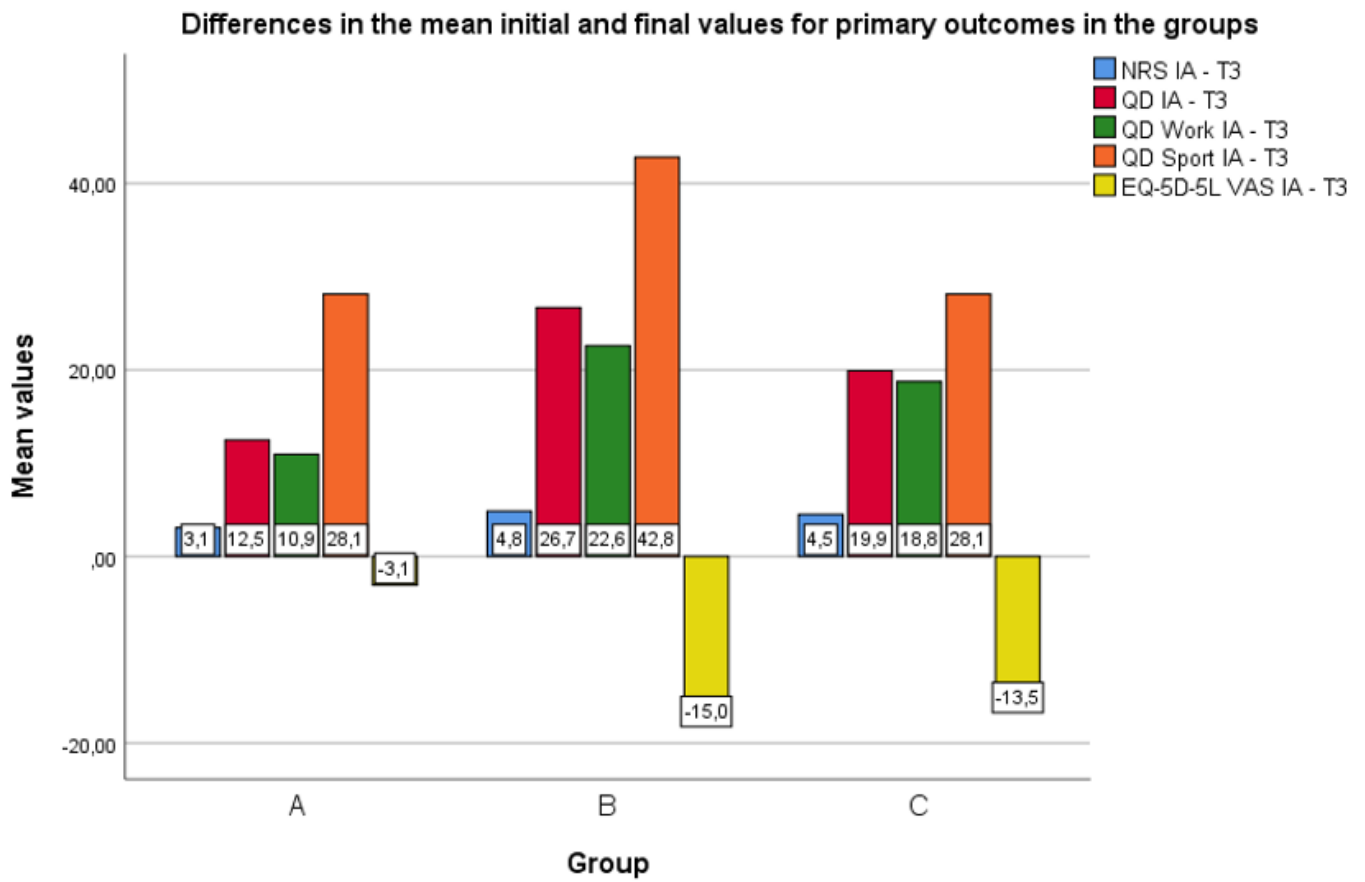


Figure 5

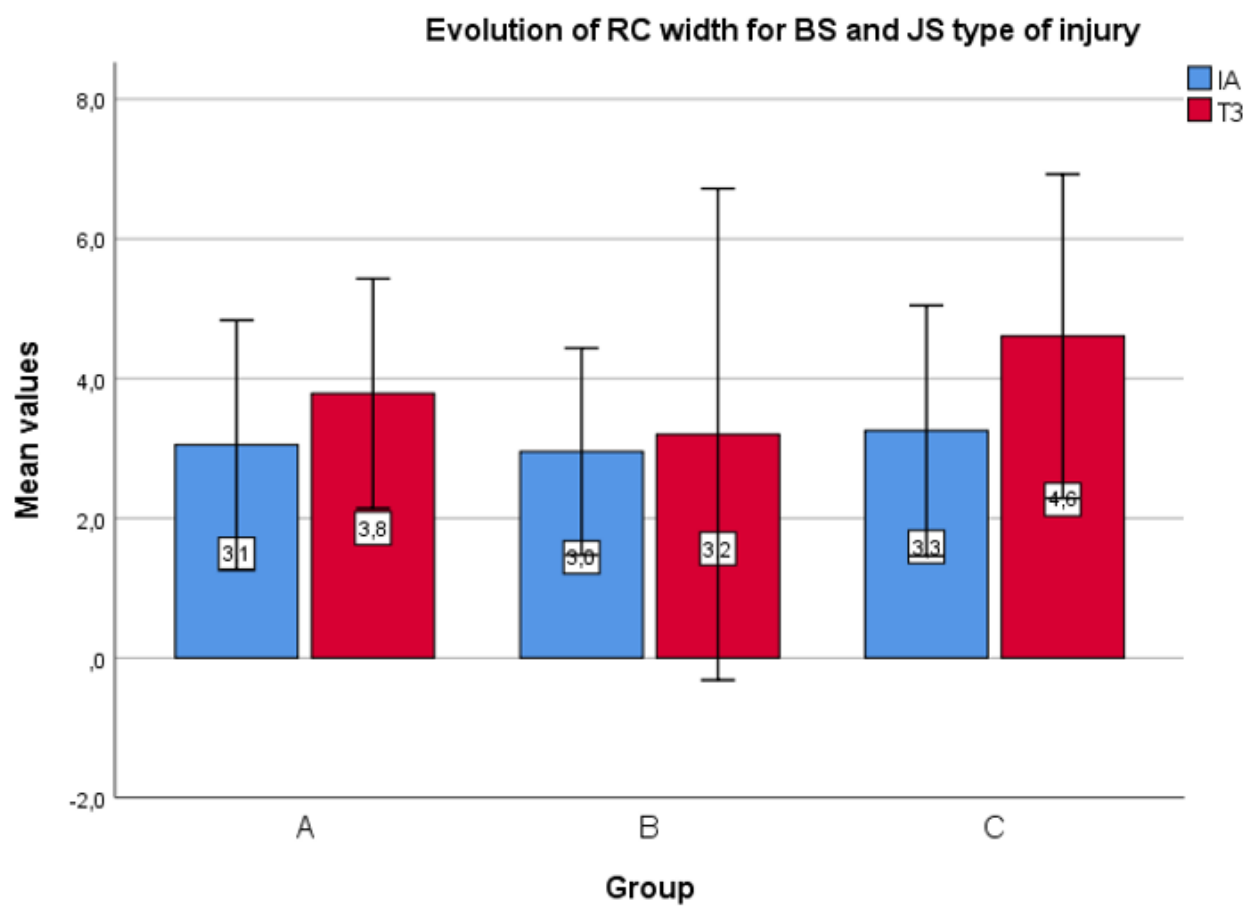
EQ-5D-5L Index evolution in the groups.





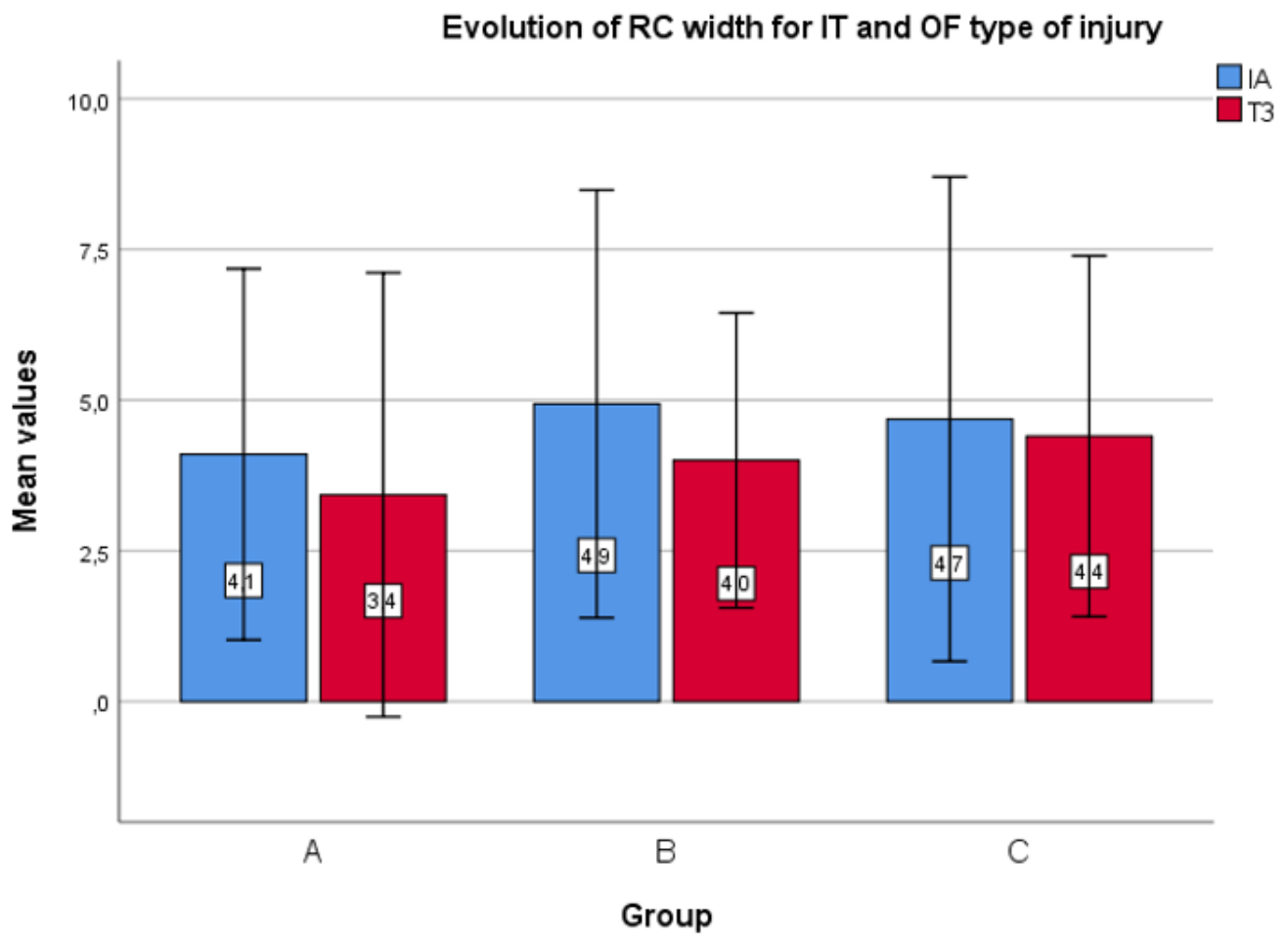
**Figure 6**

Differences in the mean initial and final values for primary outcomes in the groups.



**Figure 7**

Mean increase of width for BS and JS type of injury for specific groups.



**Figure 8**

Mean reduction of width for IT and OF type of injury for specific groups.